



**PRESENTING CLINICAL SIGNS**

**DATE** History: Pre-I131 evaluation. No murmur.

**ECHOCARDIOGRAPHIC FINDINGS**

2D, M-mode, and Doppler study.

**PERFORMED BY:** Left atrial size is normal. The mitral valve is normal. Left ventricular wall thickness is normal. Left ventricular internal dimensions are normal. Left ventricular systolic function is mildly hyperdynamic. The aorta and aortic valve are normal. Right atrial and right ventricular dimensions are normal. The tricuspid valve is normal. There is mild dynamic obstruction to flow in the right ventricular outflow tract. The pulmonary artery and pulmonic valve are normal. No heartworms are visualized. No shunting lesions are visualized. No pericardial effusion or cardiac masses are seen.

Dr. Meredith Swart  
**INTERPRETED BY**  
Keith Blass, DVM,  
MS, DACVIM  
(Cardiology)

LA/Ao – 1.45  
IVSd – 5.1 mm  
LVPWd – 5.1 mm  
LVIDd – 13.2 mm  
LVIDs – 6.0 mm  
FS – 54.5%  
LVOT – 1.25 m/s  
RVOT – 2.30 m/s

**PATIENT**

Atila Cayer

**SPECIES**

Feline

**ASSESSMENT/RECOMMENDATIONS**

Normal echocardiogram

**BREED**

This examination demonstrates no evidence of structural heart disease. As such, no contraindication to I131 therapy is appreciated in the image set.

**DSH**

Atila does have mild dynamic obstruction to flow in her right ventricular outflow tract, which could potentially result in the auscultation of a functional/innocent murmur.

**SEX**

No therapy is recommended based on this exam.

**FS**

A recheck echocardiogram is recommended if new physical exam and/or clinical abnormalities suggestive of cardiac dysfunction develop.

**AGE**

14 y

**WEIGHT**

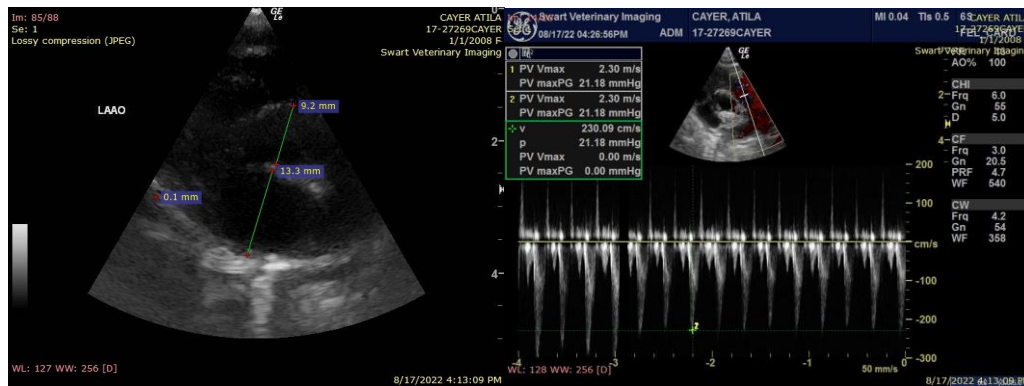
7.3 lb

**HOSPITAL NAME**

Swart Veterinary  
Imaging

**REFERRING VET**

Dr. Swart



The information and recommendations provided are based on the images presented by the referring veterinarian. No evaluation can be communicated regarding pathology that was not visible in the image/video clips provided.



Thank you for this referral. If the clinical or image interpretation does not parallel your findings or if I can be of any further assistance please contact me.

**DATE**

8/17/22

**Keith Blass, DVM, MS, DACVIM (Cardiology)**  
KeithBlass@gmail.com  
631-804-5754

**PERFORMED BY:**

Dr. Meredith Swart

**INTERPRETED BY**

Keith Blass, DVM,  
MS, DACVIM  
(Cardiology)

**PATIENT**

Atila Cayer

**SPECIES**

Feline

**BREED**

DSH

**SEX**

FS

**AGE**

14 y

**WEIGHT**

7.3 lb

**HOSPITAL NAME**

Swart Veterinary  
Imaging

**REFERRING VET**

Dr. Swart